



**PATIENT**

Tucker Graves

**SPECIES**

Canine

**BREED**

Pitbull Mix

**SEX**

Male Neutered

**AGE**

3 years

**WEIGHT**

60lbs

**PRESENTING CLINICAL SIGNS**

History: Tucker was noted to have a heart murmur in October 2020. Needs mass removal. Good appetite and activity level. On exam: NSR, grade II/VI murmur with PMI left apical area, PSS, lung fields clear. BP: 160 mmHg x 5. \*No sedation

**ECHOCARDIOGRAM FINDINGS**

2D, m-mode, color flow and Doppler imaging is available.

**Left ventricle:** The LV diameter is normal with adequate myocardial function. LV wall thicknesses are normal.

**Left atrium:** The left atrium is normal in dimension.

**Mitral valve:** The mitral valve is normal with no prolapse into the left atrial lumen. No mitral regurgitation.

**Aortic valve/aorta:** The aortic valve is normal in morphology and mobility. Mildly elevated aortic outflow velocity; laminar flow. No aortic insufficiency.

**Right ventricle:** Normal right ventricular diameter and morphology indicating no overt evidence of pulmonary arterial hypertension.

**Right atrium:** Normal RA dimension.

**Tricuspid valve:** The tricuspid valve appears normal with no tricuspid regurgitation.

**Pulmonic valve/pulmonary artery:** The pulmonic valve is normal in morphology and mobility. No pulmonic insufficiency. Normal RVOT velocity; laminar flow.

**Heart rhythm:** ECG reveals a sinus rhythm with an average HR of 120bpm.

**INTERPRETED BY**

Maggie Machen  
Lamy, DVM  
DACVIM (Cardiology)

**2-Dimensional Measurements**

|                    |     |
|--------------------|-----|
| Ao diam (cm)       | 2.2 |
| LA diam (cm)       | 2.8 |
| LA:Ao (Swe)        | 1.3 |
| IVS thickness (cm) | 0.8 |
| LVID diastole (cm) | 3.6 |
| PW thickness (cm)  | 0.8 |
| LVID systole (cm)  | 2.4 |
| FS (%)             | 33  |

**Doppler Measurements**

|                |     |
|----------------|-----|
| PV Vmax (m/s)  | 1.4 |
| AoV Vmax (m/s) | 2.5 |
| MR Vmax (m/s)  | NA  |
| TR Vmax (m/s)  | NA  |
| TR PG (mmHg)   | NA  |

**IMAGING PERFORMED BY**

Pamela Harrigan,  
RDCS

**INTERPRETATION OF THE FINDINGS**

The only cause of a murmur identified is increased flow velocity through the LVOT/aortic root. No obvious subaortic ridge or valvular abnormalities are visualized, and in the absence of structural abnormalities this is considered a benign flow murmur. If this is a new murmur, it is reasonable to monitor periodically via recheck echocardiography in the future. Additionally, screening for fluid status abnormalities (dehydration, anemia, etc.) is recommended through routine lab work as these abnormalities would make this finding more prevalent. No significant valvular insufficiencies were noted, and no structural issues identified.

**HOSPITAL NAME**

Mass Veterinary Services

**REFERRING VET**

Dr. Masloski

Prognosis is good.

**INVOICE**

24126

**RECOMMENDATIONS**

- No cardiac medications are indicated.
- Baseline lab work recommended if not recently performed.
- No cardiac contraindication for general anesthesia.

**DATE**

5/10/22



**PATIENT**

- Monitor for development of a cough, labored breathing, exercise intolerance or collapse episodes.

Tucker Graves

**SPECIES**

**PLAN**  
Recommend recheck echocardiogram in 12-18 months to screen for progression or development of concurrent cardiac disease that the preexisting murmur may mask.

Canine

**BREED**

**IMAGES**

Pitbull Mix

**SEX**

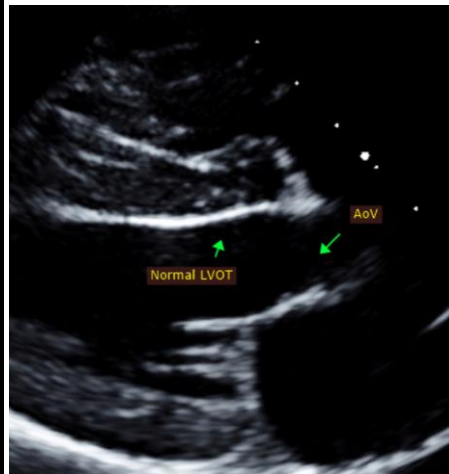
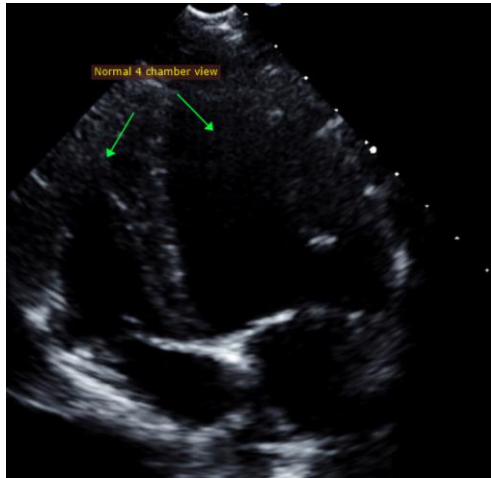
Male Neutered

**AGE**

3 years

**WEIGHT**

60lbs



**INTERPRETED BY**

The information and recommendations provided are based on the images presented by the referring veterinarian. No evaluation can be communicated regarding pathology that was not visible in the image/video clips provided.

Maggie Machen Lamy, DVM  
DACVIM (Cardiology)

Thank you for this referral. This report was generated using transcription software, and minor dictation errors may be present. If the clinical or image interpretation does not parallel your findings or if I can be of any further assistance please contact me.

**IMAGING PERFORMED BY**

Pamela Harrigan, RDCS

**Maggie Machen Lamy, DVM**  
Diplomate of the American College of Veterinary Internal Medicine (Cardiology)  
info@sonopath.com

**HOSPITAL NAME**

Mass Veterinary Services

**Echocardiogram performed by:** Pamela Harrigan, RDCS  
Pet Animal Ultrasound Service (4paus.com)

**REFERRING VET**

Dr. Masloski

**INVOICE**

24126

**DATE**

5/10/22